



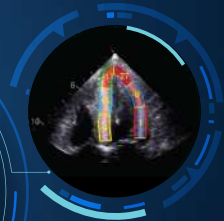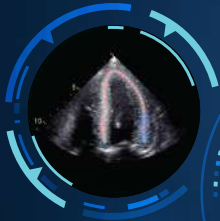
Echocardiography Practical Points for **CARDIAC AMYLOIDOSIS**

Dr. Nitin Burkule

MBBS, MD, DM (Card.)
DNB (Card.), FACC, FASE,
FSCMR

Dr. Satish Govind

MBBS, MD, PhD



Preface

Transthyretin amyloid cardiomyopathy (ATTR-CM), a life-threatening, progressive, and infiltrative form of cardiomyopathy, is increasingly recognized cause of diastolic heart failure and mortality worldwide. Rapid advances in non-invasive diagnostic modalities and disease awareness have shifted ATTR-CM from a difficult to diagnose and treat disease to a disease that can be suspected early, based on red flags and diagnosed with available non-invasive diagnostic modality.

Despite the advances in non-invasive diagnosis of cardiac amyloidosis (CA), the majority of patients with ATTR-CM do not receive a timely diagnosis. Many patients often undergo multiple rounds of consultations before receiving a correct diagnosis. From the echocardiographic point of view, we noticed a lack of practical guidance, which describes the manifestation of disease on echocardiographic imaging and interpretation and abnormality in echocardiographic parameters specific to CA. This is an important need gap in cardiology clinical practice considering the pivotal role of echocardiography in raising suspicion of CA.

In response, “Echocardiography Practical Points for Raising Suspicion of Cardiac Amyloidosis” is developed, which will help and empower the clinicians, and cardiologists to understand the key echocardiographic features to raise suspicion and facilitate an early diagnosis of cardiac amyloidosis on echocardiography.


Dr. Satish Govind

President,
Indian Academy of Echocardiography



Index

What is cardiac amyloidosis?	01
When to Suspect Transthyretin Amyloid Cardiomyopathy (ATTR-CM)	03
Echocardiography overview	04
When to suspect CA on Echocardiography	05
Characteristic features of Cardiac Amyloidosis	06
• LV thickening and the ECG	07
• LV thickening (M-mode)	08
• Tissue doppler – restrictive filling pattern and diastolic dysfunction	09
• Tissue doppler – septal mitral annulus and systolic & diastolic dysfunction	10
• LA dysfunction	11
• RV dysfunction	12
• Speckle tracking echocardiography of LV - Septal apical basal ratio	13
• Speckle tracking echocardiography of LV - Relative apical sparing Index	14
• Pericardial effusion	15
Echocardiography score and cardiac amyloidosis likelihood	17
Diagnostic Algorithm	18
Acknowledgement	19



What is

Cardiac Amyloidosis?

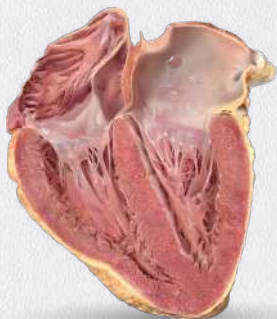Cardiac amyloidosis (CA) is a cardiomyopathy resulting from the myocardial accumulation of **misfolded protein deposits, or amyloid fibrils**. CA most commonly results from one of the following two protein precursors¹:

- **Immunoglobulin light chain amyloid fibril protein (AL)** - Amyloid fibrils form from misfolded monoclonal immunoglobulin light chain protein produced by bone marrow plasma cells¹
- **Transthyretin amyloid fibril protein (ATTR)** - Amyloid fibrils form from misfolded transthyretin (TTR), a serum transport protein for thyroid hormone and retinol that is synthesized primarily by the liver¹

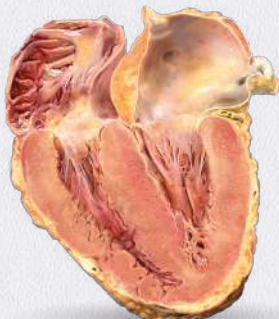In **Transthyretin amyloid cardiomyopathy (ATTR-CM)**, the TTR tetramer dissociates into monomers that then misfold and aggregate into non-native oligomers and amyloid fibrils, which accumulate extracellularly in organs and tissues, particularly the heart. The amyloid protein deposits cause the heart walls to become stiff, resulting in the inability of the left ventricle to properly relax and fill with blood and adequately squeeze to pump blood out of the heart.²⁻³ Because the symptoms of ATTR, amyloidosis are often similar to those of other diseases, the condition can be difficult to recognize and diagnose properly.⁴ ATTR-CM is considered as an under-recognised cause of certain cardiovascular conditions, such as heart failure with preserved ejection fraction (HFpEF), arrhythmia, and aortic stenosis, particularly in older adults.⁵⁻⁷

ATTR-CM is a **progressive disease** associated with **high levels of impairment**, including in physical health, quality of life, and reduced productivity.⁸ Once diagnosed, untreated patients have a **median survival of approximately 2 to 3.5 years.**⁹ Hence, an **early diagnosis and treatment of ATTR-CM is critical.**¹⁰

Normal Heart



Amyloid Heart



Illustrative representation of Normal and Amyloid Heart (Long axis view)

References: **1.** Dorbala S, Ando Y, Bokhari S, Dispenzieri A, Falk RH, Ferrari VA, Fontana M, Gheysens O, Gillmore JD, Glaudemans AWJM, Hanna MA, Hazenberg BPC, Kristen AV, Kwong RY, Maurer MS, Merlini G, Miller EJ, Moon JC, Murthy VL, Quarta CC, Rapezzi C, Ruberg FL, Shah SJ, Slart RHJA, Verberne HJ, Bourque JM. ASNC/AHA/ASE/EANM/HFSA/ISA/SCMR/SNMMI Expert Consensus Recommendations for Multimodality Imaging in Cardiac Amyloidosis: Part 1 of 2-Evidence Base and Standardized Methods of Imaging. *Circ Cardiovasc Imaging*. 2021 Jul;14(7):e000029. doi: 10.1161/HCI.000000000000029. Epub 2021 Jul 1. PMID: 34196223. **2.** Kittleson MM, Maurer MS, Ambardekar AV, Bullock-Palmer RP, Chang PP, Eisen HJ, Nair AP, Nativi-Nicolau J, Ruberg FL; American Heart Association Heart Failure and Transplantation Committee of the Council on Clinical Cardiology. Cardiac Amyloidosis: Evolving Diagnosis and Management: A Scientific Statement From the American Heart Association. *Circulation*. 2020 Jul 7;142(1):e7-e22. doi: 10.1161/CIR.0000000000000792. Epub 2020 Jun 1. Erratum in: *Circulation*. 2021 Jul 6;144(1):e10. Erratum in: *Circulation*. 2021 Jul 6;144(1):e11. PMID: 32476490. **3.** Wittles RM, Bokhari S, Darny T, Elliott PM, Falk RH, Fine NM, Gospodinova M, Obici L, Rapezzi C, Garcia-Pavia P. Screening for Transthyretin Amyloid Cardiomyopathy in Everyday Practice. *JACC Heart Fail*. 2019 Aug;7(8):709-716. doi: 10.1016/j.jchf.2019.04.010. Epub 2019 Jul 10. PMID: 31302046. **4.** Rapezzi C, Lorenzini M, Longhi S, Milandri A, Gagliardi C, Bartolomei I, Salvi F, Maurer MS. Cardiac amyloidosis: the great pretender. *Heart Fail Rev*. 2015 Mar;20(2):117-24. doi: 10.1007/s10741-015-9480-0. PMID: 25758359. **5.** González-López E, Gallego-Delgado M, Guzzo-Merello G, de Haro-Del Moral FJ, Cobo-Marcos M, Robles C, Bornstein B, Salas C, Lara-Pezzi E, Alonso-Pulpon L, Garcia-Pavia P. Wild-type transthyretin amyloidosis as a cause of heart failure with preserved ejection fraction. *Eur Heart J*. 2015 Oct 7;36(38):2585-94. doi: 10.1093/eurheartj/ehv338. Epub 2015 Jul 28. PMID: 26224076. **6.** Castaño A, Narotsky DL, Hamid N, Khalique OK, Morgenstern R, DeLuca A, Rubin J, Chluzan C, Nazif T, Vahl T, George I, Kodali S, Leon MB, Hahn R, Bokhari S, Maurer MS. Unveiling transthyretin cardiac amyloidosis and its predictors among elderly patients with severe aortic stenosis undergoing transcatheter aortic valve replacement. *Eur Heart J*. 2017 Oct 7;38(38):2879-2887. doi: 10.1093/eurheartj/ehx350. PMID: 29019612; PMCID: PMC5837725. **7.** Ruberg FL, Grogan M, Hanna M, Kelly JW, Maurer MS. Transthyretin Amyloid Cardiomyopathy: JACC State-of-the-Art Review. *J Am Coll Cardiol*. 2019 Jun 11;73(22):2872-2891. doi: 10.1016/j.jacc.2019.04.003. PMID: 31171094; PMCID: PMC6724183. **8.** Stewart M, Shaffer S, Murphy B, Loftus J, Alvir J, Cicchetti M, Lenderking WR. Characterizing the High Disease Burden of Transthyretin Amyloidosis for Patients and Caregivers. *Neurol Ther*. 2018 Dec;7(2):349-364. doi: 10.1007/s40120-018-0106-z. Epub 2018 Aug 2. PMID: 30073497; PMCID: PMC6283802. **9.** Maurer MS, Elliott P, Comenzo R, Semigran M, Rapezzi C. Addressing Common Questions Encountered in the Diagnosis and Management of Cardiac Amyloidosis. *Circulation*. 2017 Apr 4;135(14):1357-1377. doi: 10.1161/CIRCULATIONAHA.116.024438. PMID: 28373528; PMCID: PMC5392416. **10.** Elliott P, Drachman BM, Gottlieb SS, Hoffman JE, Hummel SL, Lenihan DJ, Ebebe B, Gundapaneni B, Li B, Sultan MB, Shah SJ. Long-Term Survival With Tafamidis in Patients With Transthyretin Amyloid Cardiomyopathy. *Circ Heart Fail*. 2022 Jan;15(1):e008193. doi: 10.1161/CIRCHEARTFAILURE.120.008193. Epub 2021 Dec 20. PMID: 34923848; PMCID: PMC8763250

When to Suspect Transthyretin Amyloid Cardiomyopathy (ATTR-CM)

Cardiac

- ▶ Hypotensive or normotensive if previously hypertensive
- ▶ Atrial fibrillation together with conduction system disorders
- ▶ Increased LV wall thickness
- ▶ Arrhythmias and conduction defects with HFpEF
- ▶ Infiltration of the atrioventricular and sinoatrial nodes
- ▶ Cardiac conduction abnormalities
- ▶ Low-flow and low-gradient aortic stenosis
- ▶ Cardiogenic shock due to diffuse ischemia (although rare)
- ▶ Pseudo infarct pattern with low/decreased QRS voltage on ECG
- ▶ Disproportionally elevated NT-proBNP to degree of HF
- ▶ Persistently elevated troponin levels
- ▶ Increased valve thickness
- ▶ Subendocardial LGE
- ▶ Abnormal gadolinium kinetics
- ▶ Increased extracellular volume

Extracardiac

- ▶ **Soft tissue infiltrations:** purpura (advanced disease), bilateral carpal tunnel syndrome/ weakness or paresthesia of hands, atraumatic biceps tendon rupture, lumbar spinal stenosis
- ▶ **Nervous system:** peripheral neuropathy and dysautonomia
- ▶ **Gastrointestinal tract:** diarrhea and/or constipation, nausea and vomiting, and early satiety, leading to weight loss
- ▶ **Ophthalmological:** glaucoma, intravitreal deposition and scalloped pupils
- ▶ **Liver and kidney:** hepatomegaly (advanced disease) and renal disease (rare)

Reference: Chander Mohan J, Dalal J, Chopra VK, Narasimhan C, Kerkar P, Oommen A, Ray Fcsi S, Sharma AR, Dougall P, Simon S, Verma Dm A, Radhakrishnan V. Suspecting and diagnosing transthyretin amyloid cardiomyopathy (ATTR-CM) in India: An Indian expert consensus. Indian Heart J. 2022 Nov-Dec;74(6):441-449. doi: 10.1016/j.ihj.2022.11.006. Epub 2022 Nov 21. PMID: 36410415; PMCID: PMC9773277.

Echocardiography overview

The diagnosis of cardiac amyloidosis requires the clinician to be mindful of clinical features (clues or “red flags”) that are associated with the cardiac amyloidosis phenotype as well as the diagnostic tools that assist in identifying the disease.¹ Echocardiography is one of the non-invasive cardiac imaging modalities, which can play a major role in raising suspicion and diagnosis of cardiac amyloidosis due to its,

- 1) Unmatched ability to combine safety with vast amount of diagnostic information,
- 2) Superior diastolic function and structure assessment capacity and,
- 3) Bedside and widespread availability and portability.² It is indispensable in the management of almost every patient with a known or suspected cardiac illness.

References: 1. Writing Committee: Kittleson MM, Ruberg FL, Ambardekar AV, Brannagan TH, Cheng RK, Clarke JO, Dember LM, Frantz JG, Hershberger RE, Maurer MS, Nativi-Nicolau J, Sancharawala V, Sheikh FH. 2023 ACC Expert Consensus Decision Pathway on Comprehensive Multidisciplinary Care for the Patient With Cardiac Amyloidosis: A Report of the American College of Cardiology Solution Set Oversight Committee. *J Am Coll Cardiol.* 2023 Mar 21;81(11):1076-1126. doi: 10.1016/j.jacc.2022.11.022. Epub 2023 Jan 23. Erratum in: *J Am Coll Cardiol.* 2023 Mar 21;81(11):1135. PMID: 36697326. 2. Cuddy SAM, Chetrit M, Jankowski M, Desai M, Falk RH, Weiner RB, Klein AL, Phelan D, Grogan M. Practical Points for Echocardiography in Cardiac Amyloidosis. *J Am Soc Echocardiogr.* 2022 Sep;35(9):A31-A40. doi: 10.1016/j.echo.2022.06.006. PMID: 36064258.

Cardiac amyloidosis

should be suspected on

echocardiography

when

- Concentric left ventricular hypertrophy (LVH) with a progressive increase in wall thickness
- Biventricular hypertrophy with normal to small cavities
- Granular and sparkling appearance of myocardium
- Severe left ventricle (LV) diastolic dysfunction, dilated left atrium (LA) with severely impaired LV longitudinal shortening
- Intracardiac thrombus and small pericardial effusion
- Thickened valve leaflets and inter-atrial septum
- Reduced LV global longitudinal strain (GLS) with apical sparing

Reference: Garcia-Pavia P, Rapezzi C, Adler Y, Arad M, Basso C, Brucato A, Burazor I, Caforio ALP, Damy T, Eriksson U, Fontana M, Gillmore JD, Gonzalez-Lopez E, Grogan M, Heymans S, Imazio M, Kindermann I, Kristen AV, Maurer MS, Merlini G, Pantazis A, Pankuweit S, Rigopoulos AG, Linhart A. Diagnosis and treatment of cardiac amyloidosis: a position statement of the ESC Working Group on Myocardial and Pericardial Diseases. *Eur Heart J.* 2021 Apr 21;42(16):1554-1568. doi: 10.1093/eurheartj/ehab072. PMID: 33825853; PMCID: PMC8060056.

Characteristic features of **CARDIAC AMYLOIDOSIS ON ECHOCARDIOGRAPHY**

- LV thickening and the ECG
- LV thickening (M-mode)
- Tissue doppler - restrictive filling pattern and diastolic dysfunction
- Tissue doppler - septal mitral annulus and systolic & diastolic dysfunction
- LA dysfunction
- RV dysfunction
- Speckle tracking echocardiography of LV - Septal apical basal ratio
- Speckle tracking echocardiography of LV - Relative apical sparing Index
- Pericardial effusion

Left ventricle thickening & the ECG

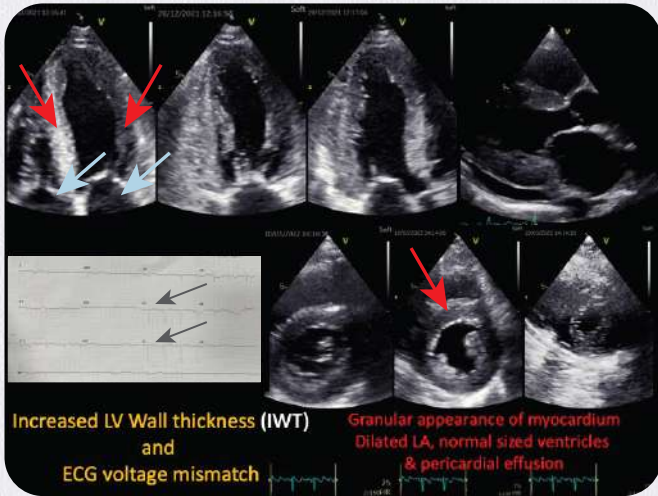


Figure 1: Echocardiographic images are seen with the **top row** (apical - 4, 2 and 3 chamber views) and **bottom row** (parasternal short axis views at- mitral valve, papillary muscles and apical levels) showing severe left ventricular hypertrophy due to myocardial amyloid infiltration (**red arrows**)

The ECG shows a paradoxical finding- typical low-voltage complexes not reflecting thickened LV walls and a characteristic pseudo-infarction pattern (**black arrows**)

Also, note the echocardiographic images (apical views) showing a granular and sparkling appearance of the myocardium (**red arrows**) and thickened mitral and tricuspid leaflets (**blue arrows**)

Left ventricle thickening

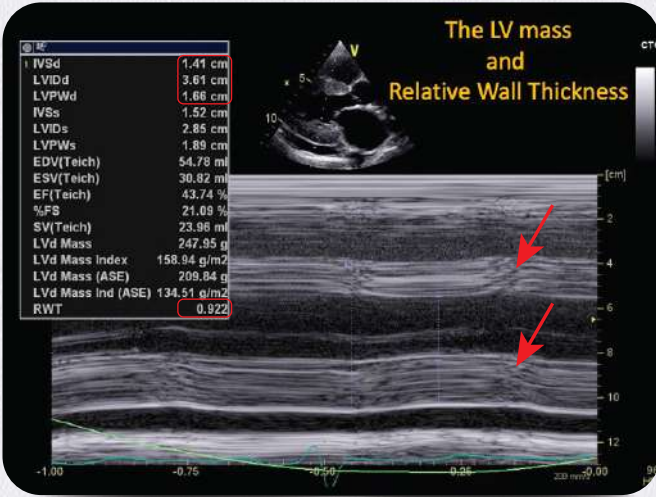


Figure 2: M-mode of the left ventricle (LV) showing thickened LV walls (**red arrows**). Very high relative wall thickness is present (RWT=0.9). Measurements are shown in the red highlighted boxes.

Reduced LV cavity size and increased LV mass.

Diastolic dysfunction

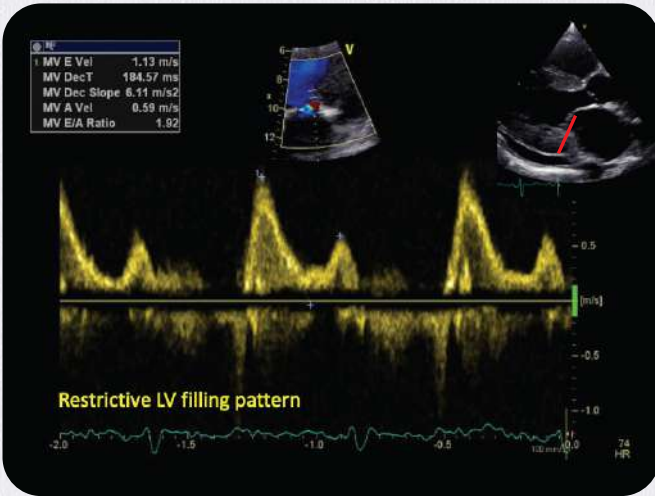


Figure 3: Doppler echocardiography shows a restrictive filling pattern on spectral Doppler across the mitral valve (E/A=1.92)

Tissue doppler imaging of septal mitral annulus

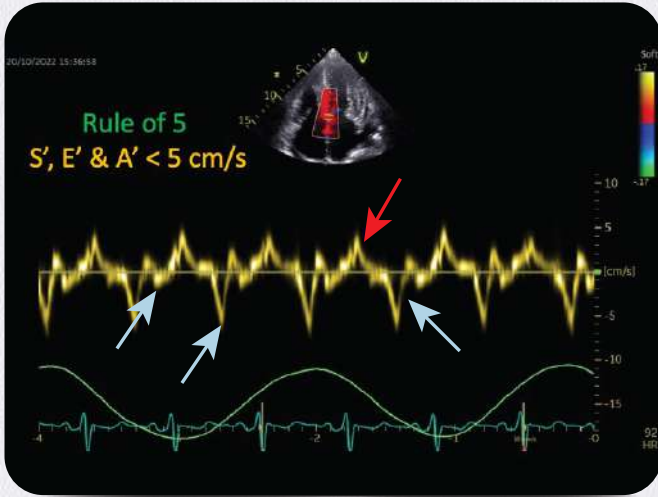


Figure 4: The systolic velocities, reflecting left ventricular (LV) longitudinal shortening- **S' (red arrow)** and diastolic velocities, reflecting LV diastolic function- **E', A' (blue arrow)** are significantly reduced.

Due to a severely impaired LV longitudinal function, the S', E' and A' are close to 5 cm/s. E'/e' ($113/5 = 22$) is significantly increased, indicating high LV filling pressure.

Left atrial dysfunction

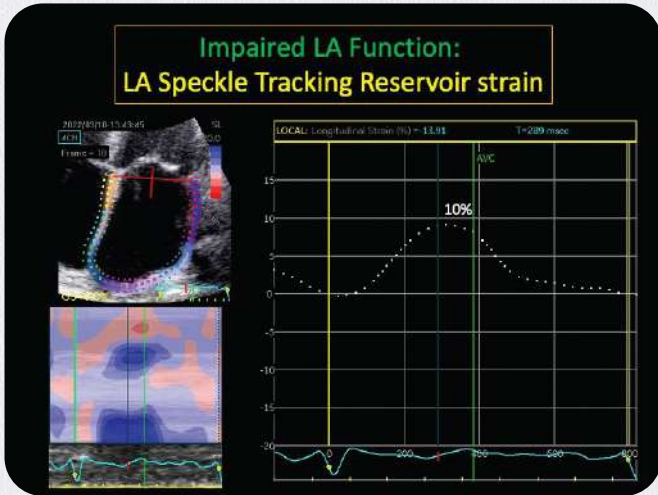


Figure 5: Speckle tracking echocardiography shows severely impaired Left atrial (LA) reservoir strain (10%). The amyloid deposition in the thin LA myocardium causes LA electro-mechanical dysfunction and high incidence of clot formation.

Right ventricular dysfunction

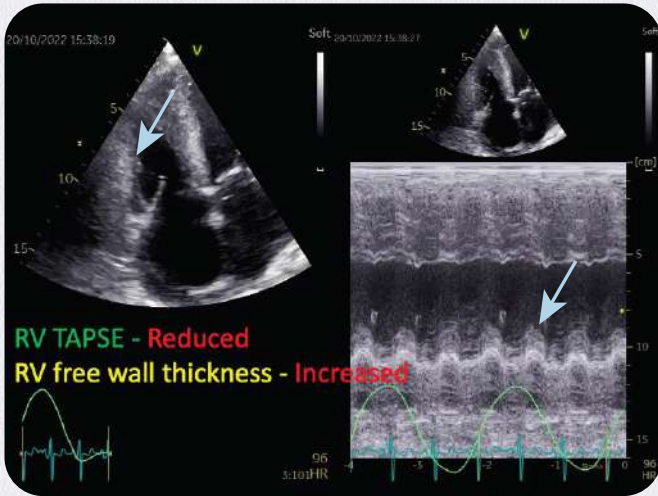


Figure 6: An echocardiographic image of the right ventricle (RV) seen in the RV-focused apical-4 chamber view. There is a thickening of the RV free wall (**blue arrow**).

The m-mode of tricuspid annulus on the right side shows reduced RV systolic function as assessed by tricuspid annular plane systolic excursion (TAPSE = 1.1 cm).

Speckle tracking echocardiography of LV

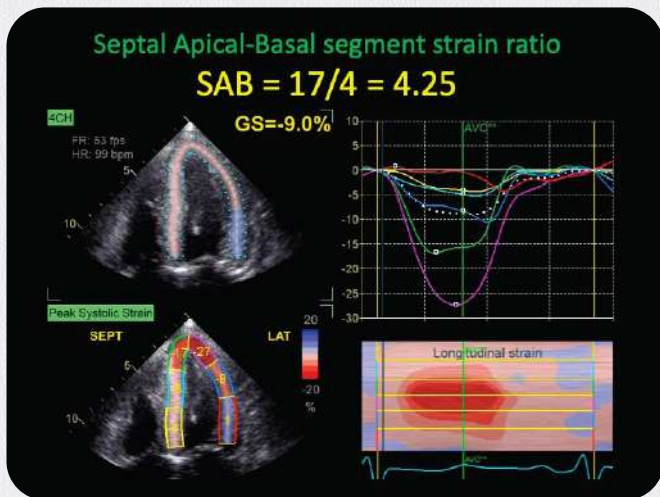


Figure 7: Apical-4 chamber view of the left ventricle (LV) shows segmental strain in the left lower images. Note the low strain numbers in the mid and basal segments and the high strain numbers in the apical segments (called apical sparing).

Septal apical/basal (SAB) strain ratio can be calculated ($17/4 = 4.25$).

SAB >3 is highly specific for cardiac amyloid.

Speckle tracking echocardiography of LV

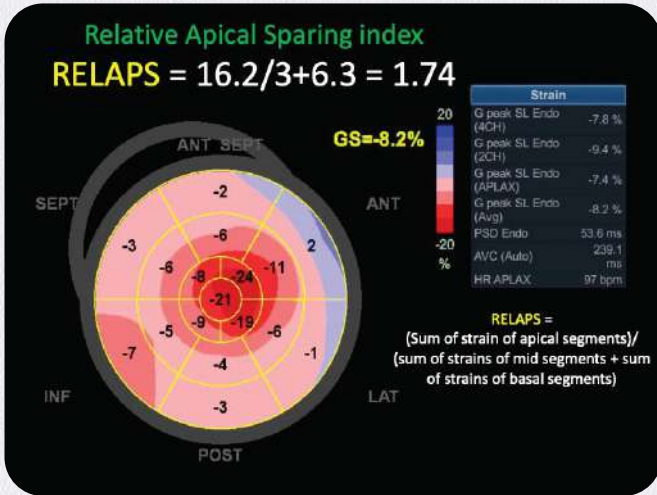


Figure 8: LV Apical sparing- Speckle tracking echocardiography shows a bulls-eye plot of the left ventricular (LV) regional segments. The mid and basal segments are pink, indicating very low segmental strain. In comparison, note the apex, which is red, indicating better segmental strain. This is called LV apical sparing. The global longitudinal strain (GLS) is severely reduced (GLS=-8.2%). A high LV ejection fraction (EF) to global longitudinal strain (GLS) ratio of >4 is highly specific for cardiac amyloid.

An accurate calculation of apical sparing can be made by RELAPS (relative apical sparing) index. Average strain of apical segments/ average strain of mid-segments+average strain of basal segments. (16.2/6.3+3=1.74).

RELAPS >1 is highly specific for cardiac amyloid.

Pericardial effusion

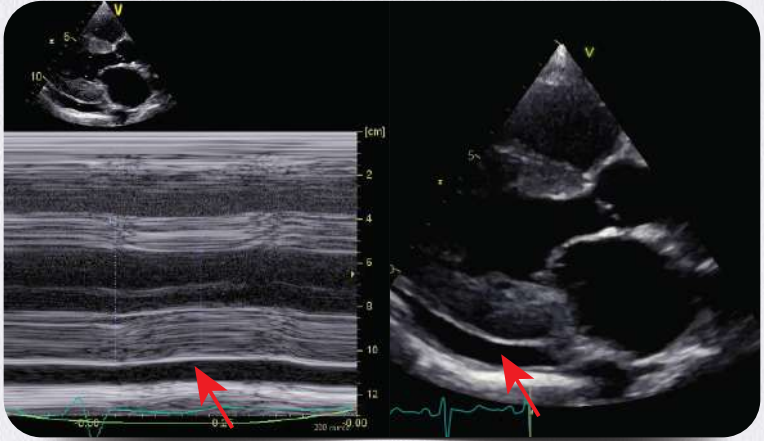


Figure 9: Pericardial effusion- Parasternal long axis showing pericardial effusion posterior to the left ventricle (**red arrows**).

INCREASED WALL THICKNESS SCORE

DIAGNOSTIC ALGORITHM

Increased Wall Thickness Score

A Proposed multi-parametric echocardiographic approach/score with highly sensitive and highly specific cutoffs to diagnose or exclude cardiac amyloidosis in patients with increased wall thickness by Boldrini et. al.¹ In patients with a hypertrophic phenotype, IWT Score can be used to guide the diagnostic algorithm, avoid unnecessary tests, and limit the time to diagnosis.¹

RWT >0.6

3 points

E/e' >11

1 point

SAB >2.9

3 points

TAPSE <19 mm

2 points

GS <13%

1 point

Increased wall thickness score

Sensitivity 98%
Specificity 19%

**<2 points
CA
Unlikely**

Sensitivity 61%
Specificity 27%

**2-7 Perform
Additional
Test**

Sensitivity 46%
Specificity 98%

**≥ 8 points
CA**

RWT: Relative wall thickness. **TAPSE:** Tricuspid annular plane systolic excursion. **SAB:** Systolic apex-to-base ratio.

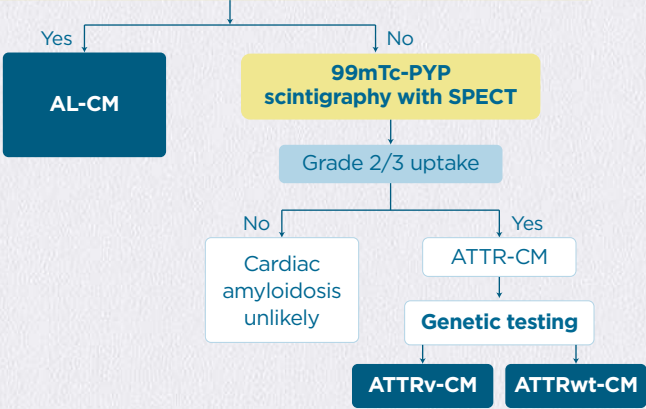
IWT: Increased wall thickness. **E/e':** E-wave/e0-wave. **GS:** Global strain. **CA:** Cardiac amyloidosis.

Reference: 1. Adapted from Boldrini M, Cappelli F, Chacko L, Restrepo-Cordoba MA, Lopez-Sainz A, Giannoni A, Aimo A, Baggiano A, Martinez-Naharro A, Whelan C, Quarta C, Passino C, Castiglione V, Chubuchnyi V, Spini V, Taddei C, Vergaro G, Petrie A, Ruiz-Guerrero L, Moñivas V, Mingo-Santos S, Mirelis JG, Dominguez F, Gonzalez-Lopez E, Perlini S, Pontone G, Gillmore J, Hawkins PN, Garcia-Pavia P, Emdin M, Fontana M. Multiparametric Echocardiography Scores for the Diagnosis of Cardiac Amyloidosis. JACC Cardiovasc Imaging. 2020 Apr;13(4):909-920. doi: 10.1016/j.jcmg.2019.10.011. Epub 2019 Dec 18. PMID: 31864973.

Diagnostic Algorithm for Cardiac Amyloidosis

Clues from history, ECG, echocardiogram, CMR

- Serum protein electrophoresis with immunofixation
 - Urine protein electrophoresis with immunofixation
 - Serum free light chain assay
- Monoclonal protein?**
- Serum kappa/lambda free light chain (abnormal if ratio is <0.26 or >1.65)
 Serum/urine IFE (abnormal if monoclonal protein detected)



AL-CM: Amyloid monoclonal immunoglobulin light chain cardiomyopathy. **ATTR-CM:** Amyloid transthyretin cardiomyopathy. **ATTRv-CM:** Variant transthyretin amyloid cardiomyopathy. **ATTRwt-CM:** Wild-type transthyretin amyloid cardiomyopathy. **CMR:** Cardiac magnetic resonance. **ECG:** Electrocardiogram. **IFE:** Immunofixation electrophoresis. **K/L:** Kappa/lambda. **PYP4:** pyrophosphate. **SPEP/UPEP:** Serum/urine protein electrophoresis.

Adapted from: Kittleson MM, Ruberg FL, Ambardekar AV, Brannagan TH, Cheng RK, Clarke JO, Dember LM, Frantz JG, Hershberger RE, Maurer MS, Nativi-Nicolau J, Sanchorawala V, Sheikh FH. 2023 ACC Expert Consensus Decision Pathway on Comprehensive Multidisciplinary Care for the Patient With Cardiac Amyloidosis: A Report of the American College of Cardiology Solution Set Oversight Committee. J Am Coll Cardiol. 2023 Mar 21;81(11):1076-1126. doi: 10.1016/j.jacc.2022.11.022. Epub 2023 Jan 23. Erratum in: J Am Coll Cardiol. 2023 Mar 21;81(11):1135. PMID: 36697326.

Acknowledgement



Indian Academy of Echocardiography

DSM-141, 1st floor, DLF tower
15-Shivaji Marg, Main Najafgarh Road
New Delhi- 110015



Dr. Nitin Burkule

Director
Department of Cardiology
Jupiter Hospital
Eastern Express Highway, Mumbai- 400601



Dr. Satish Govind

Chief of Non-invasive Cardiology
Narayana Institute of Cardiac Sciences
NN Health City, Bangalore- 560099
and President
India Academy of Echocardiography

ATTR-CM: Transthyretin Amyloid Cardiomyopathy. **CA:** Cardiac amyloidosis. **E/e':** E-wave/e'-wave. **ECG:** Electrocardiogram. **EF:** Ejection fraction. **GLS:** Global longitudinal strain. **IVS:** Interventricular septum. **IWT:** Increased wall thickness. **LA:** Left atrium. **LV:** Left ventricle, ventricular. **LVEF:** Left ventricular ejection fraction. **LVOTO:** Left ventricular outflow tract obstruction. **M-mode:** Motion mode. **RA:** Right atrium. **RELAPS:** relative apical sparing index. **RV:** Right ventricle. **RWT:** Relative wall thickness. **SAB:** Systolic apex-to-base Ratio. **TAPSE:** Tricuspid annular plane systolic excursion.

Disclaimer:

This message is intended for Registered Medical Practitioners authorized to practice in India.

This content is intended for your personal and educational use only. Please do not share or distribute this material. Reproduction or distribution of this content, in whole or in part, is not permitted without the permission of the copyright owner(s).


All information published herein is intended and strictly only for informational, educational, academic and/or research purposes and shall not be utilized to diagnose or treat a health problem or disease without referring to the full prescribing information for list of approved indications as contained in the package insert.

While due care and caution has been taken to ensure that the content here is free from mistakes or omissions, Pfizer makes no claims, promises, or guarantees about the accuracy, completeness, or adequacy of the information here.

The views expressed by any author herein are their own independent views and Pfizer may not necessarily endorse the same.

The echocardiographic images are provided by the author.

You may report an adverse event related to Pfizer products by emailing us at IND.AEReporting@pfizer.com or via Fax at: 000800100-5961 / +91-22 3919-771



Pfizer Limited, The Capital – B Wing, 1802, 18th floor, Plot No. C-70, G Block, Bandra Kurla Complex, Bandra (East), Mumbai 400 051, India.